

UNUSUAL DEATH BY HANGING IN AN AGRICULTURAL WELL: HOMICIDE OR SUICIDE?

Nataraja Moorthy T^{1*}, Sairah Karim²

^{1*} Corresponding author and Professor of Forensic Sciences, Faculty of Health and Life Sciences (FHLS), Management and Science University (MSU), Section 13, Shah Alam, Selangor, Malaysia. Formerly Government Forensic Crime Scene Investigator (India)

² Dean, Faculty of Health and Life Sciences, Management and Science University, Shah Alam, Selangor, Malaysia.

Abstract

Background: Death scene investigations, particularly hanging cases, confuse the police officer to conclude. Sometimes, the circumstances raise a reasonable suspicion that some other person has committed an offence. **Gist of the case:** A village boy aged 21 years was found hanging inside an agricultural land. It was alleged that somebody had murdered the youth and hanged the body in the inner wall of the well. The Police Inspector arrived and registered under "suspicious death" and forensic service was requisitioned to examine the peculiar type of hanging incident. **Crime Scene Observation:** The body was removed after documentation and examined by the field criminalist. No struggling marks in the well area, nor external injuries on the body of the deceased were noticed. The deceased neck showed a twisted coconut fibre rope with a non-continuous ligature mark. **Conclusion:** Based on the crime scene examination and findings, suggested the possibility of suicidal hanging only.

Keywords: Crime Scene Investigation, Youth, Hanging, Agricultural Well, Alleged Homicide

INTRODUCTION

The process of crime scene investigation is not only about the aspects of scene security, documentation, and collection of physical evidence but still requires more dynamic approaches like keen crime scene examination, hypotheses development through the linkage of the scene, physical evidence, persons and finally, the reconstruction of the crime scene [1]. In recent scenarios, crime scene investigators are facing challenges in solving the mystery because of the tactics of criminals that confuse the investigators, in particular, whenever dealing with dead bodies [2]. When considering the death, the occurrence may be either natural or unnatural. Unnatural death may occur by suicide, homicide, accident, mass disasters and many others [3]. Sometimes, a person may commit suicide, but circumstances raise a reasonable suspicion that some other person has committed an offence. In death investigations, the body posture may cause confusion and complications for the crime scene investigators to explain. It may occur in the context of suicide or a body found in a non-residential or outer area [4]. Suicide is the way of ending one's own life. The manner of suicide varies from country to country, and common methods include hanging, poisoning, self-immolation and so on. In India, the suicide rate of females is comparatively higher than males, and many married women have been committing suicide for many reasons [5]. In unnatural mortality, hanging or self-suspension is a form of ligature strangulation, one of the most used suicide methods. Hanging may result from either incomplete or complete suspension of the body. When the whole body hangs off the ground, and the entire weight of the victim is suspended at the neck, the hanging is said to be complete. Incomplete hanging or partial hanging implies that some part of the body is touching the ground, and the weight of the victim is not fully supported by the neck [6]. The incidence of hanging cases differs depending on the community, geographical location, and socio-economic condition [7]. Depending on the circumstances and environmental factors, complete and incomplete hanging may result from suicidal or homicidal hanging. Crime scenes contain physical evidence pertinent to an investigation [8], and hanging deaths show characteristics of proof on the bodies [9]. The present hanging report is very peculiar and rare, wherein a young man hangs in an agricultural water well. The parents and relatives alleged murder. The corresponding author and former Forensic Crime Scene Investigator (TN) examined the scene and dead body, suggested the possibility of suicide, and ruled out the homicide act [10,11]. The crime scene finding was later confirmed by the autopsy examination.

GIST OF THE CASE

A village boy aged 25 years was found hanging in an agricultural water well located about 2 km from the village in Tamil Nadu. He belonged to this same village, and the scene was first noticed by a farmer of the agricultural land, who informed the Police. The Inspector of Police visited and registered a case u/s "suspicious death" and requisitioned the service of a forensic crime scene investigator, District Mobile Forensic Science Laboratory to visit and assist the police investigation. Upon receipt of the message from the Inspector of Police, the corresponding author (herein as TN), then the Government Forensic Crime Scene Investigator, arrived at the

crime scene.

FORENSIC CRIME SCENE EXAMINATION

On arrival at the scene of the crime, TN observed the scene and made preliminary enquiries with the villagers. It is a complete hanging inside a well, as shown in Figure 1. The well was medium deep, in the middle of a farmer's agricultural land.




Figure 1. Hanging dead body inside the well

The body was found hanging about eight feet from the motor pump placed just below the ground level, with a twisted coconut fibre ligature. The ligature point is a fixed structure to which the other end of the ligature material is tied in hanging [9]. Here, the ligature point is a heavy iron water pump, and the other end is the neck. The body was found hanging in between the wall of the well and the water pipe, with the body touching the wall. The direction of the ligature mark was known from the position of the knot. The knot was on the left side of the neck (left mastoid) and tilted to the right. He wore a checked, folded, full-handed shirt, unbuttoned with a folding lungi. To make a thorough close-up external examination of the dead body and for autopsy examination, the hanging body was removed from the place of hanging and laid on the ground, as shown in Figure 2. The eyes and the mouth opened slightly with a twisted coconut fibre rope around the neck with a knot at the left side below the ear.

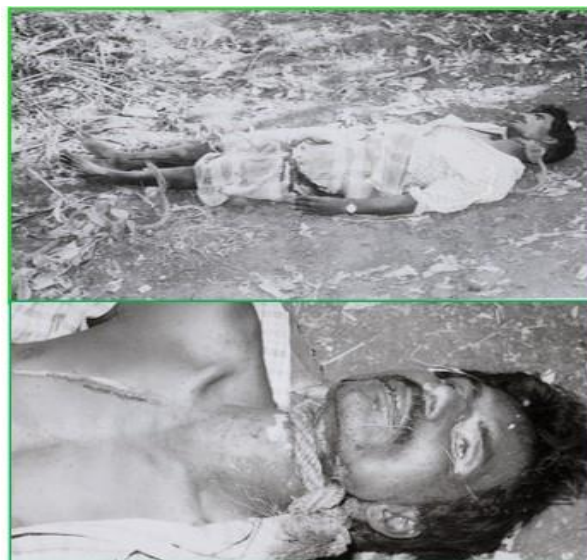

Figure 2. Close-up view of the victim and ligature position

The ligature mark on the neck was oblique rather than encircled under the string. There was a discharge of faecal and blood from the penis and anus that crawled to the feet, usually occurring in a suicidal hanging. Some scratch marks on the body were due to the friction of the body on the rough, irregular wall rock in the well while jumping with rope on the neck. These valuable indications are characteristics of suicidal hanging rather than homicide acts [9,10]. Police investigation showed that the reason for death was due to his petty quarrel with his parents.

DISCUSSION

Hanging is one of the ten leading causes of death in the world, accounting for more than a million deaths annually [12]. In India, hanging is one of the common methods of committing suicide, along with poisoning, burning and drowning [13]. Over the past 30 years, the incidence of suicide by hanging has increased, especially among young adults. In the present report, the deceased was a young adult. For hanging, the ligature material used mainly by males was hard materials like jute rope, nylon rope and electrical wires, while females used soft materials like clothes, sarees, etc [14]. Following these findings, a twisted coconut fibre rope was used in this report. Regarding the place of hanging and the ligature points, the home was the most typical place for females, while the choice of males was out of the house viz., trees in the forest, barren land, and agricultural farms [15]. But in this case report, the deceased had chosen an atypical agricultural water well, which has never been recorded in any literature. The primary motivating factor observed in this suicide report was domestic/family-related issues rather than medical issues or diseases [16] and the findings following this report.

CONCLUSION

The forensic crime scene investigation concluded with the finding of an atypical hanging since the body was found hanging inside an agricultural water well. In the present investigation report, an alleged homicidal hanging was ruled out forensically and confirmed to be a suicidal hanging based on the keen examination of the scene and dead body.

REFERENCES

- [1] Henry CL, Elaine MP (2013). Forensic evidence and crime scene investigation. *J Foren Inves*.1 (2): 1-5.
- [2] Nataraja Moorthy T (2020). Crime reconstruction, a tool to solve the mystery and achieve justice an interesting crime scene report. *Egypt J Foren Sci Appli Tox*. 20 (4): 86-89.
- [3] Nataraja Moorthy T, Sairah Karim, Doaa El Morsi (2024). Partial bloodstained foot Impressions identified the perpetrator in a violent crime: A rare crime scene investigation report. *GAP India J Foren Behavi Sci*.5 (1): 6-10.
- [4] Nataraja Moorthy.(2007) Forensics of suspicious death. *Tamilnadu Police J*. 2007; July-Sept: 78-99.
- [5] Panda PK, Mishra US.(2021). Unnatural death in India. *J Biosocial Sci*.53 (3): 367-378.
- [6] Janakrai NP *et al* (2020). Insight into pathophysiology and management of partial hanging. *Int Surg J*. 7(2):451-454.
- [7] Jaykant K, Manoj K, Mayank G. (2018). A medicolegal study of death due to hanging in Varanasi region. *Indian J Appl Res*.8(2):33-34.
- [8] Nataraja Moorthy T. (2020). A suicide case with homicidal simulation- case report of a real fabricated crime scene. *Int J Med Tox Legal Med*.23(3-4):128-130.
- [9] Vipul NA, Nilesh T, Satin M, Jaydeo B. (2015). Ligature material in hanging deaths: The neglected area in forensic examination. *Egypt J Forensic Sci*.5:109-113.
- [10] Nataraja Moorthy T. (2019). Footprint evidence solved the mystery in a suspicious death: A rare case report. *Peer Revi J Foren Gene Sci*. 3(2): 183-185.
- [11] Nataraja Moorthy, Nadiyah SM, Sivadurai SN, Saravanan K. (2022). Revenue Divisional Officer's inquiry on a newly-wed woman's disputed death: Toe impression indicated the cause of death – A real crime scene report. *GAP India J Foren Behavi Sci*.3(1): 14-17.
- [12] Ambade VN, Keoliya AN, Wankhede AG.(2012). Availability of means of suicides. *Int J Med Tox Leg Med*.14: 83-89.
- [13] Gunnell D, Bennewith O, Hawton K, Simkin S, Kapur N. (2006). The epidemiology and prevention of suicide by hanging: a systematic review. *Int J Epidemiol*.34(2):433-442.
- [14] Dinesh Rao.(2016). An autopsy study of death due to suicidal hanging. *Egypt J Foren Sci*.6: 248- 254.
- [15] Nataraja Moorthy, Noor Shafarina S, Kannan N.(2022). Skull-photo superimposition technique identified the partial hanging of unknown dead: Real crime reconstruction report. *GAP Indian J Foren Behavior Sci*. 3(2): 1-5.
- [16] Saisudheer T, Nagaraja TV. (2012). A study of ligature marks in cases of hanging deaths. *Int J Pharm Biomed Sci*.3(3):80-84.